



# Bariatric Surgical Practice During the Initial Phase of COVID-19 Outbreak

Ali Aminian<sup>1</sup> · Mohammad Kermansaravi<sup>2</sup> · Shahriar Azizi<sup>3</sup> · Peyman Alibeigi<sup>4</sup> · Sina Safamanesh<sup>5</sup> · Ali Mousavimaleki<sup>2</sup> · Mohammad Taghi Rezaei<sup>4</sup> · Maziar Faridi<sup>5</sup> · Somayeh Mokhber<sup>2</sup> · Abdolreza Pazouki<sup>2</sup> · Saeed Safari<sup>6</sup>

© Springer Science+Business Media, LLC, part of Springer Nature 2020

## Abstract

There is no data on patients with severe obesity who developed coronavirus disease 2019 (COVID-19) after bariatric surgery. Four gastric bypass operations, performed in a 2-week period between Feb 24 and March 4, 2020, in Tehran, Iran, were complicated with COVID-19. The mean age and body mass index were  $46 \pm 12$  years and  $49 \pm 3$  kg/m<sup>2</sup>. Patients developed their symptoms (fever, cough, dyspnea, and fatigue) 1, 2, 4, and 14 days after surgery. One patient had unnoticed anosmia 2 days before surgery. Three patients were readmitted in hospital. All 4 patients were treated with hydroxychloroquine. In two patients who required admission in intensive care unit, other off-label therapies including antiretroviral and immunosuppressive agents were also administered. All patients survived. In conclusion, COVID-19 can complicate the postoperative course of patients after bariatric surgery. Correct diagnosis and management in the postoperative setting would be challenging. Timing of infection after surgery in our series would raise the possibility of hospital transmission of COVID-19: from asymptomatic patients at the time of bariatric surgery to the healthcare workers versus acquiring the COVID-19 infection by non-infected patients in the perioperative period.

**Keywords** Bariatric surgery · Gastric bypass · Complications · COVID-19 · Coronavirus · Pneumonia

## Introduction

The rising pandemic of novel coronavirus disease 2019 (COVID-19), caused by severe acute respiratory syndrome coronavirus 2 (SARS-CoV-2), is a worldwide crisis for global health and economy. Although the infection has been reported

all around the world in the first few months of the year 2020, the clinical presentation and outcomes of surgical patients during the COVID-19 outbreak have not been clearly characterized [1]. In response to this progressive global health crisis, following the advice by the governmental and professional authorities [2, 3], bariatric surgical practice, which is an elective surgical procedure, has been temporarily stopped in many places around the world.

Based on the current knowledge, the median incubation period of COVID-19 is 4 days (interquartile range, 2 to 7). The time from onset to dyspnea is 5 days, 7 days to hospital admission, and 10 days to intensive care unit (ICU) admission. Fever, cough, and fatigue are the most common clinical manifestations. Other symptoms include shortness of breath, myalgia, sore throat, and headache. About 10% of patients initially present with gastrointestinal symptoms (nausea, vomiting, or diarrhea) 1 to 2 days prior to development of fever, cough, and dyspnea. Abnormal findings in chest X-ray and CT scan can be seen in 60% and > 90% of patients, respectively. The most common patterns on chest CT are ground-glass opacity

✉ Ali Aminian  
aminiaa@ccf.org

<sup>1</sup> Bariatric and Metabolic Institute, Department of General Surgery, Cleveland Clinic, 9500 Euclid Avenue, Desk M61, Cleveland, OH 44195, USA

<sup>2</sup> Minimally Invasive Surgery Research Center, Rasool-e-Akram Hospital, Iran University of Medical Sciences, Tehran, Iran

<sup>3</sup> Erfan Niayesh Hospital, Tehran, Iran

<sup>4</sup> Mehrad Hospital, Tehran, Iran

<sup>5</sup> Iranmehr Hospital, Tehran, Iran

<sup>6</sup> Firoozgar General Hospital, Iran University of Medical Sciences, Tehran, Iran

**Table 1** Clinical characteristics of 4 patients who developed COVID-19 pneumonia after bariatric surgery

	Patient 1	Patient 2	Patient 3	Patient 4
Sex	Female	Female	Female	Male
Age (year)	63	43	35	41
BMI (kg/m <sup>2</sup> )	51	50	50	44
Comorbidities	Prediabetes, GERD, OSA, DJD, PE (in past)	GERD	GERD	None
Surgery	RYGB	RYGB	RYGB	SAGB
Date of surgery	2/24/2020	2/26/2020	2/27/2020	3/4/2020
Date of symptoms	2/25/2020	3/11/2020	3/2/2020	3/6/2020 <sup>1</sup>
Presentation	Fever, dyspnea, passing out	Cough, fatigue, anorexia	Fever, cough, dyspnea, fatigue	Fever, cough, dyspnea
RT-PCR <sup>2</sup>	Positive	Positive	Positive	Not done
Chest CT	Involvement of lower lobe of left lung	Not done	Fig. 1a	Fig. 1b
White blood cell count (per $\mu$ L)	12,000	12,100	11,000	Normal
Lymphopenia <sup>3</sup>	Absent	Present	Present	Absent
CRP	Elevated	Elevated	Elevated	Elevated
ESR	Elevated	Elevated	Elevated	Not done
Liver function tests	Normal	Normal	Normal	Normal
Length of hospital stay (days)	11	4	10	0 <sup>4</sup>
Length of ICU stay (days)	1	0	3	0
Treatment <sup>5</sup>	Hydroxychloroquine, Kaletra	Hydroxychloroquine	Hydroxychloroquine, Kaletra, tocilizumab, hemoperfusion	Hydroxychloroquine, amoxicillin, clavulanate
Outcome	Survived	Survived	Survived	Survived

<sup>1</sup> Patient lost sense of smell (anosmia) 2 days before surgery

<sup>2</sup> Reverse transcriptase–polymerase chain reaction (RT-PCR) test for COVID-19 nucleic acid of nasopharyngeal swab specimen

<sup>3</sup> Defined as lymphocyte count < 1000 per  $\mu$ L of blood

<sup>4</sup> Assessed in the emergency department and was discharged home with medications for self-isolation

<sup>5</sup> Off-label and empiric

*BMI* body mass index, *CRP* c-reactive protein, *CT* computed tomography, *DJD* degenerative joint disease, *ESR* erythrocyte sedimentation rate, *GERD* gastroesophageal reflux disease, *ICU* intensive care unit, *OSA* obstructive sleep apnea, *PE* pulmonary embolism, *RYGB* Roux-en-Y gastric bypass, *SAGB* single anastomosis gastric bypass

and local or bilateral patchy shadowing [4–7]. Diagnosis can be confirmed by sequencing or reverse transcriptase–polymerase chain reaction (RT-PCR) test for COVID-19 nucleic acid of nasal and pharyngeal swab specimens. Notably, in a report from China on over 1000 patients to assess the diagnostic accuracy of different tests, chest CT scan had sensitivity of 98% compared with RT-PCR sensitivity of only 71% [8]. Major complications include acute respiratory distress syndrome (ARDS), arrhythmia, septic shock, and multiple organ failure. Overall, most cases are classified as mild (81%; i.e., nonpneumonia and mild pneumonia). However, 14% are severe and 5% are critical [4–7].

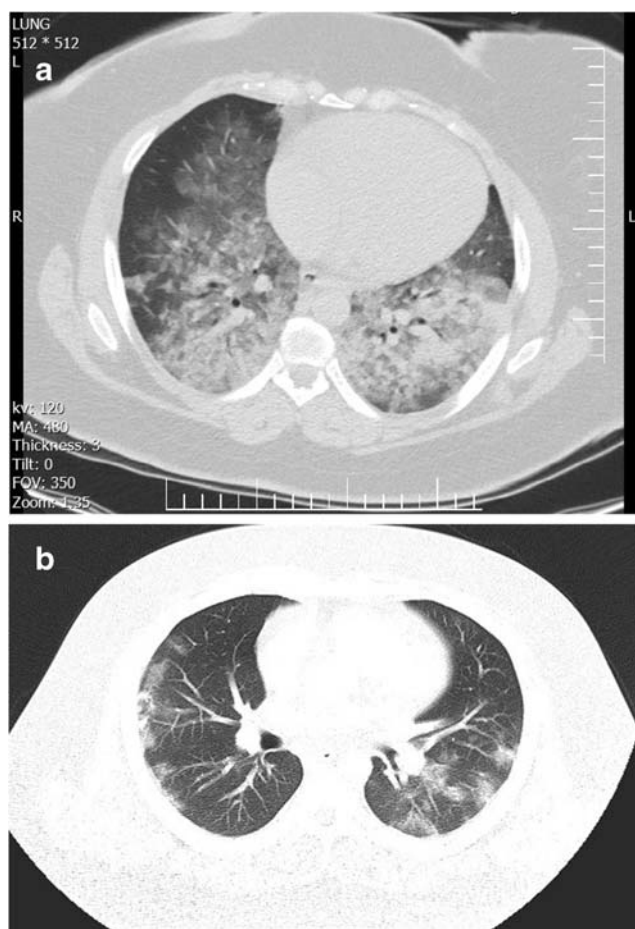
There is no data on patients with severe obesity who developed COVID-19 after bariatric surgery. The aim of this report is to describe the clinical presentation and outcomes

of bariatric surgical patients during the initial phase of COVID-19 outbreak.

## Methods

Following submission of a request on a closed social media group of Iranian bariatric surgeons who are the International Federation for the Surgery of Obesity and Metabolic Disorders (IFSO) members, 4 patients were identified who developed postoperative COVID-19 after bariatric surgery during the initial phase of outbreak in Iran.

Sixty-two surgeons in Iran are member of the IFSO with annual bariatric surgical volume of near 10,000 cases. The first case of COVID-19 in Iran, the epicenter of infection in the Middle East, was officially announced on February 19,



**Fig. 1** Chest CT scan of COVID-19 pneumonia after bariatric surgery. **a** Patient 3: Bilateral large areas of ground-glass opacities and consolidations, giving a crazy paving pattern and a white lung appearance, 4 days after gastric bypass. **b** Patient 4: Multiple bilateral peripheral ground-glass opacities 2 days after gastric bypass

2020. As of the end of April 3, 2020, there were over 53,000 laboratory-confirmed cases and near 3300 deaths in Iran.

## Results

Four gastric bypass operations (Roux-en-Y  $n = 3$ , single anastomosis  $n = 1$ ), performed in a 2-week period between Feb 24 and March 4, 2020 in Tehran, Iran, were complicated with COVID-19 pneumonia. Clinical characteristics of patients and their outcomes have been summarized in Table 1. The mean age and body mass index were  $46 \pm 12$  years and  $49 \pm 3$  kg/m<sup>2</sup>, respectively.

Patients developed their symptoms (fever, cough, dyspnea, and fatigue) 1, 2, 4, and 14 days after surgery. One patient had unnoticed anosmia 2 days before surgery. Three patients were readmitted in hospital. All 4 patients were treated with hydroxychloroquine. In two patients who required admission in intensive care unit, other off-label therapies including antiretroviral medication (Kaletra [combination of lopinavir and

ritonavir]; protease inhibitor), immunosuppressive agent (tocilizumab: monoclonal antibody against the interleukin-6 receptor), and hemoperfusion (for nonspecific removal of the circulating cytokines during cytokine storm) were also administered. Patients did not require endotracheal intubation and mechanical ventilation in the ICU. All patients survived.

## Discussion

Beginning of March 2020, given the huge burden of COVID-19 outbreak on the health care systems, critical shortage of personal protective equipment (PPE) and ventilators, and risk of hospital transmission of infection, nonessential elective surgical procedures, including bariatric surgical procedures, have been postponed in many places around the world.

Although bariatric surgical procedures are generally safe operations and patients are usually discharged the next day after surgery [9, 10], given the extent of current epidemic and limited availability of resources, temporary postponing of bariatric surgical procedures would be the right decision in many places. Sometimes the rare complications of bariatric surgery, such as bleeding, leakage, or pulmonary embolism, are difficult to manage and extremely resource demanding. Furthermore, bariatric surgical practice usually requires frequent perioperative visits by the multidisciplinary team which would not be safe in the current situation when social distancing is widely advised.

These cases raise the possibility that performing elective operative interventions on patients with undetected hidden or mild form of COVID-19 may lead to hospital transmission of COVID-19 [1, 6]. Case 4 had an undetected form of disease at the time of surgery. He lost the sense of smell 2 days before surgery, which would be the early sign of COVID-19 infection according to some anecdotal reports [11]. Case 1 and case 3 that had a short interval between the surgery and COVID-19 symptoms probably had hidden form of disease at the time of bariatric surgery. This could potentially be associated with spreading the infection to healthcare providers and contamination of operative room and equipment. Other possibility would be that cases 1, 2, and 3 were healthy and might acquire the infection during their hospital stay.

Bariatric surgical patients are at risk for development of different postoperative pulmonary complications. Obstructive sleep apnea, obesity hypoventilation, asthma, and chronic obstructive pulmonary disease are not uncommon in patients with severe obesity which can predispose them to postoperative pulmonary adverse events. Patients who develop shortness of breath or fever in the early postoperative period of bariatric surgery would require several diagnostic tests to rule out typical surgical complications such as gastrointestinal leak or pulmonary embolism. Hypoventilation, infectious pneumonia (including COVID-19 pneumonia), and pulmonary edema are other possible diagnoses.

Overall, chest CT scan has a good accuracy for diagnosing different complications in the postoperative setting including the COVID-19 pneumonia [8].

Patients with severe obesity usually have multiple comorbid conditions which would make them vulnerable to severe form of COVID-19. Severe obesity, hypertension, diabetes, and cardiopulmonary diseases have been found as risk factors for poor prognosis after COVID-19 [5–7]. In the current series of 4 bariatric patients, two patients required ICU admission. Another small series of COVID-19 patients reported high morbidity and mortality in surgical patients [1]. Since there is currently not any approved medication for COVID-19, all patients received therapies with possible benefits based on the anecdotal evidence [12]. Those included hydroxychloroquine (in all 4 patients), antiretroviral drug, immunosuppressive medication, and hemoperfusion [13].

Although, this is the first published case series of COVID-19 in bariatric surgical patients, this report has several limitations including retrospective design, small sample size, and lack of comparative data on number and characteristics of bariatric surgical patients during the study time period who did not develop COVID-19.

In conclusion, COVID-19, presenting with postoperative fever, cough, and dyspnea, can complicate the postoperative course of patients after bariatric surgery. Correct diagnosis and management in the postoperative setting would be challenging. Timing of infection after surgery in our series would raise the possibility of hospital transmission of COVID-19: from asymptomatic patients at the time of bariatric surgery to the healthcare workers versus acquiring the COVID-19 infection by non-infected patients in the perioperative period.

### Compliance with Ethical Standards

**Conflict of Interest** The authors have no declare that they have no conflicts of interest.

**Ethical Approval** For this type of study formal consent is not required.

**Informed Consent Statement** Informed consent does not apply in this study.

### References

1. Aminian A, Safari S, Razeghian-Jahromi A, et al. COVID-19 outbreak and surgical practice: unexpected fatality in perioperative period. *Ann Surg.* 2020; <https://doi.org/10.1097/SLA.0000000000003925>
2. COVID-19: Recommendations for Management of Elective Surgical Procedures. Available on <https://www.facs.org/covid-19/clinical-guidance/elective-surgery>. Accessible on 3/25/2020
3. CMS Adult Elective Surgery and Procedures Recommendations. Available on <https://www.cms.gov/files/document/31820-cms-adult-elective-surgery-and-procedures-recommendations.pdf>. Accessible on 3/25/2020
4. Holshue ML, DeBolt C, Lindquist S, et al. First case of 2019 novel coronavirus in the United States. *N Engl J Med.* 2020;382(10):929–36.
5. Guan WJ, Ni ZY, Hu Y, et al. Clinical characteristics of coronavirus disease 2019 in China. *N Engl J Med.* 2020; <https://doi.org/10.1056/NEJMoa2002032>.
6. Wang D, Hu B, Hu C, et al. Clinical characteristics of 138 hospitalized patients with 2019 novel coronavirus-infected pneumonia in Wuhan. *China JAMA.* 2020; <https://doi.org/10.1001/jama.2020.1585>.
7. Wu Z, McGoogan JM. Characteristics of and Important Lessons From the Coronavirus Disease 2019 (COVID-19) Outbreak in China: Summary of a Report of 72 314 Cases From the Chinese Center for Disease Control and Prevention. *JAMA.* 2020; <https://doi.org/10.1001/jama.2020.2648>.
8. Ai T, Yang Z, Hou H, et al. Correlation of chest CT and RT-PCR testing in coronavirus disease 2019 (COVID-19) in China: a report of 1014 cases. *Radiology.* 2020;26:200642. <https://doi.org/10.1148/radiol.2020200642>.
9. Aminian A, Brethauer SA, Kirwan JP, et al. How safe is metabolic/diabetes surgery? *Diabetes Obes Metab.* 2015;17(2):198–201.
10. Daigle CR, Brethauer SA, Tu C, et al. Which postoperative complications matter most after bariatric surgery? Prioritizing quality improvement efforts to improve national outcomes. *Surg Obes Relat Dis.* 2018;14(5):652–7.
11. Loss of sense of smell as marker of COVID-19 infection. Accessible on <https://www.entuk.org/sites/default/files/files/Loss%20of%20sense%20of%20smell%20as%20marker%20of%20COVID.pdf>. Accessible on 3/25/2020
12. Harrison C. Coronavirus puts drug repurposing on the fast track. *Nat Biotechnol.* 2020; <https://doi.org/10.1038/d41587-020-00003-1>.
13. Ronco C, Reis T, De Rosa S. Coronavirus epidemic and extracorporeal therapies in intensive care: si vis pacem para bellum. *Blood Purif.* 2020;1–4. <https://doi.org/10.1159/000507039>.

**Publisher's Note** Springer Nature remains neutral with regard to jurisdictional claims in published maps and institutional affiliations.